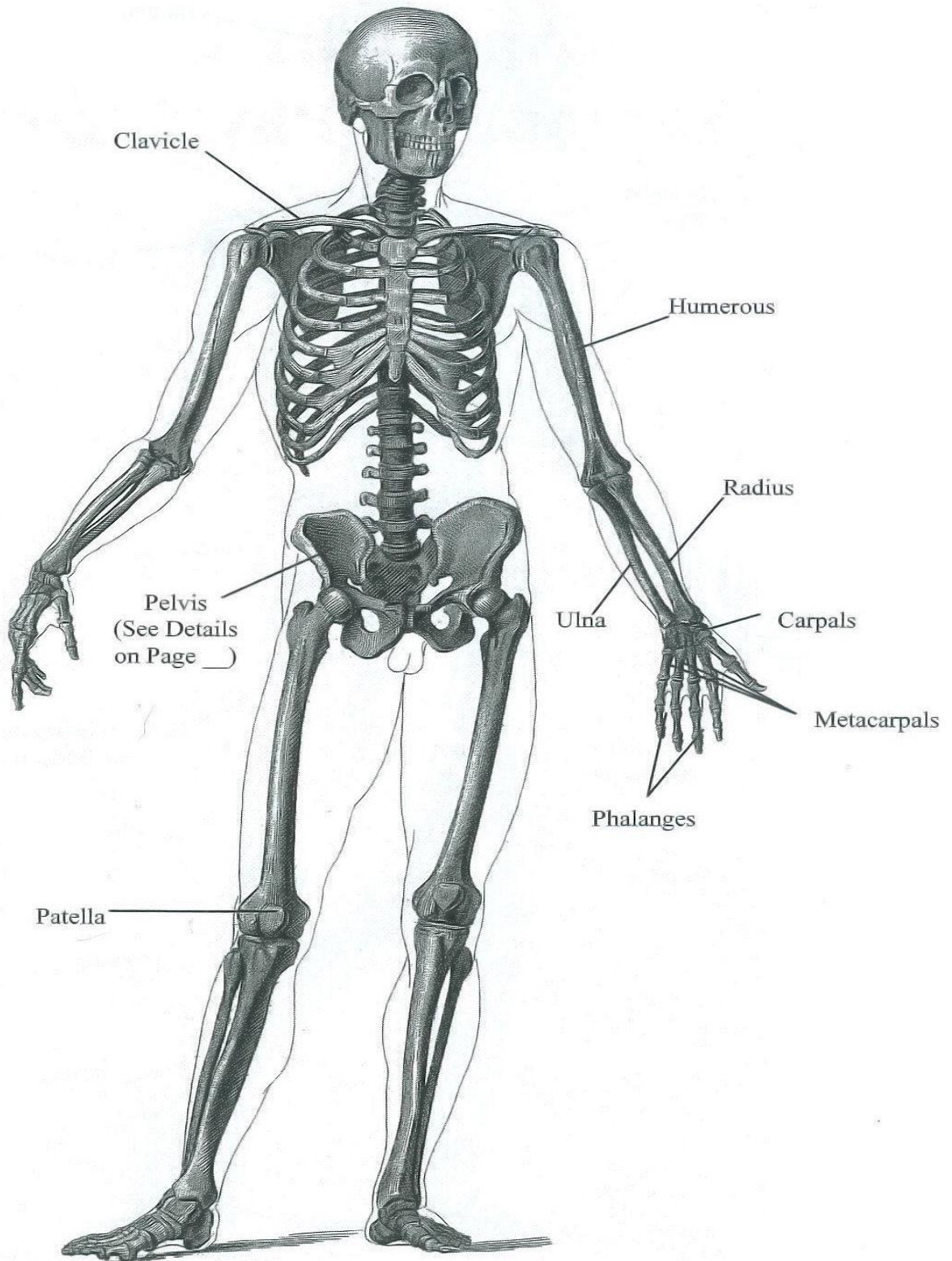
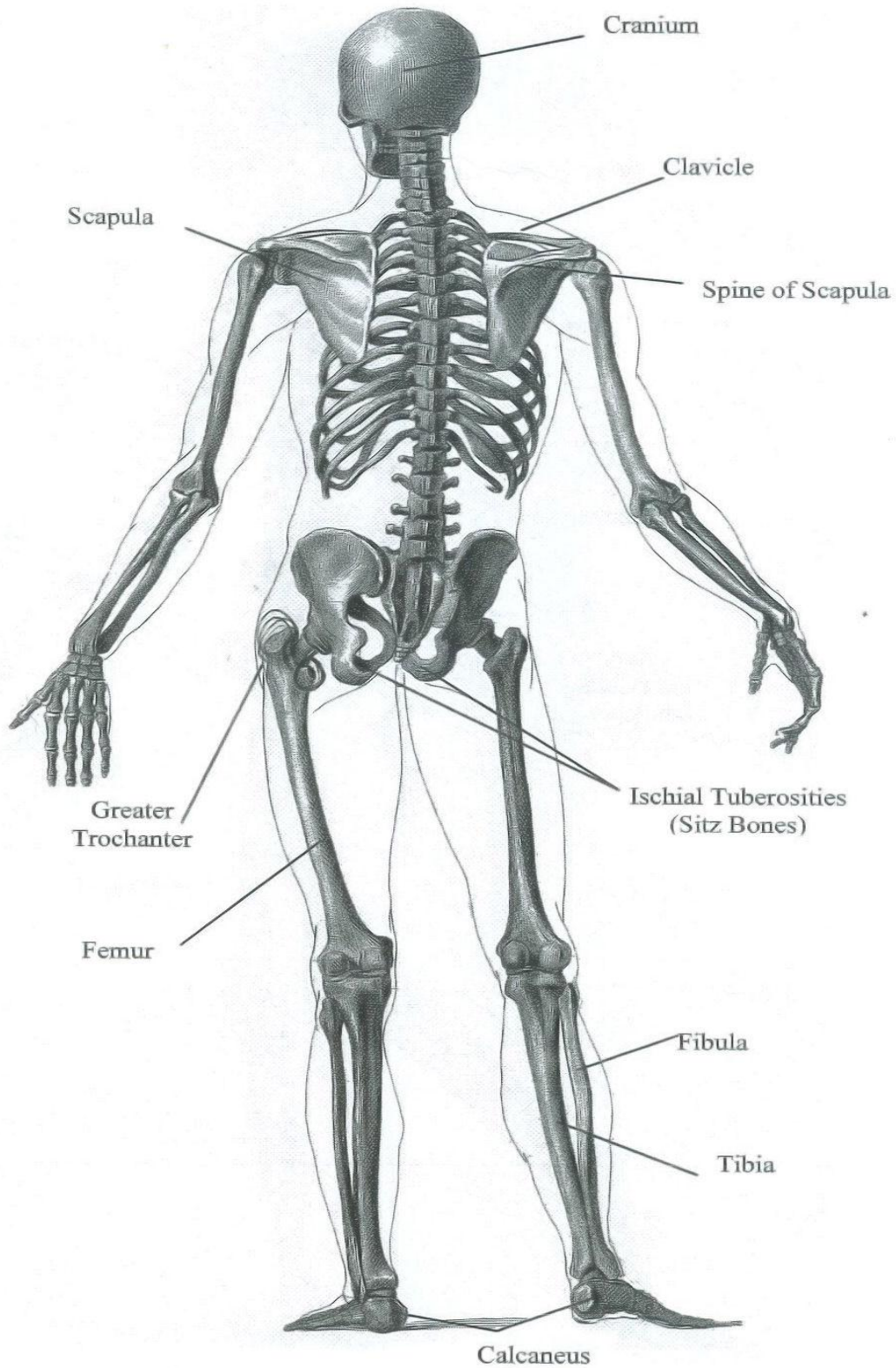


Skeleton - Anterior View



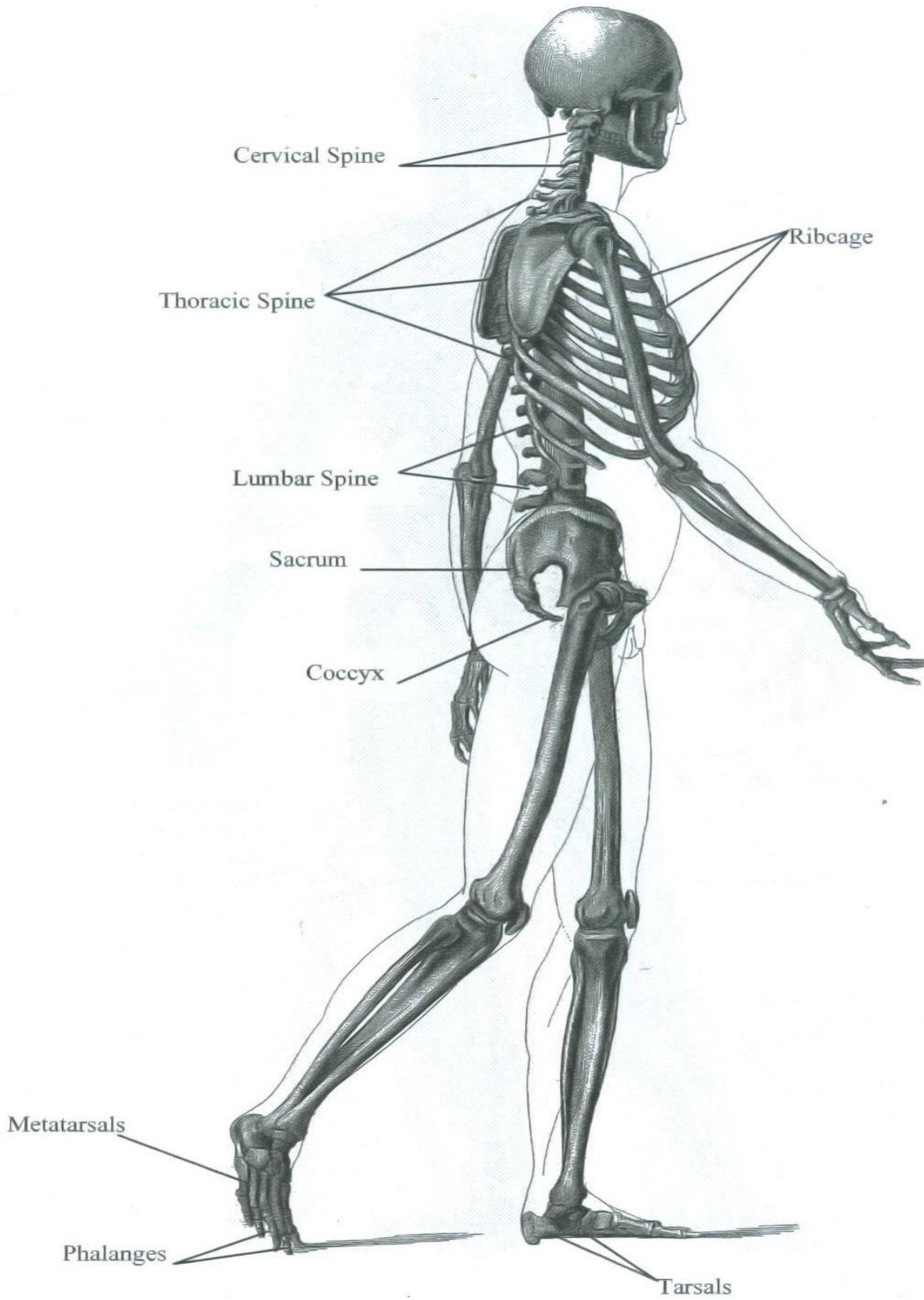
From *Heck's Pictorial Archive of Nature and Science*

Skeleton - Posterior View



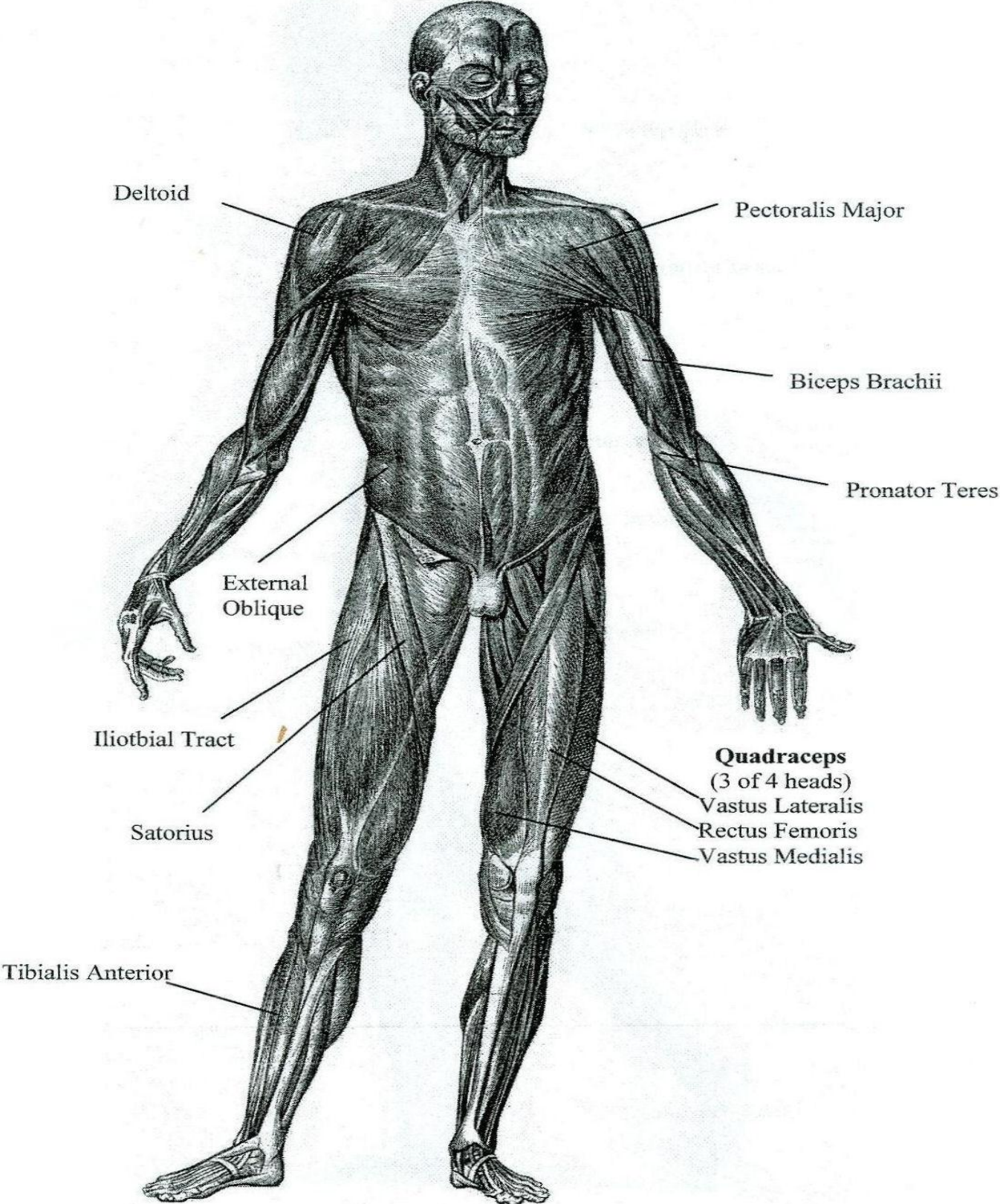
From Heck's Pictorial Archive of Nature and Science

Skeleton - Lateral View



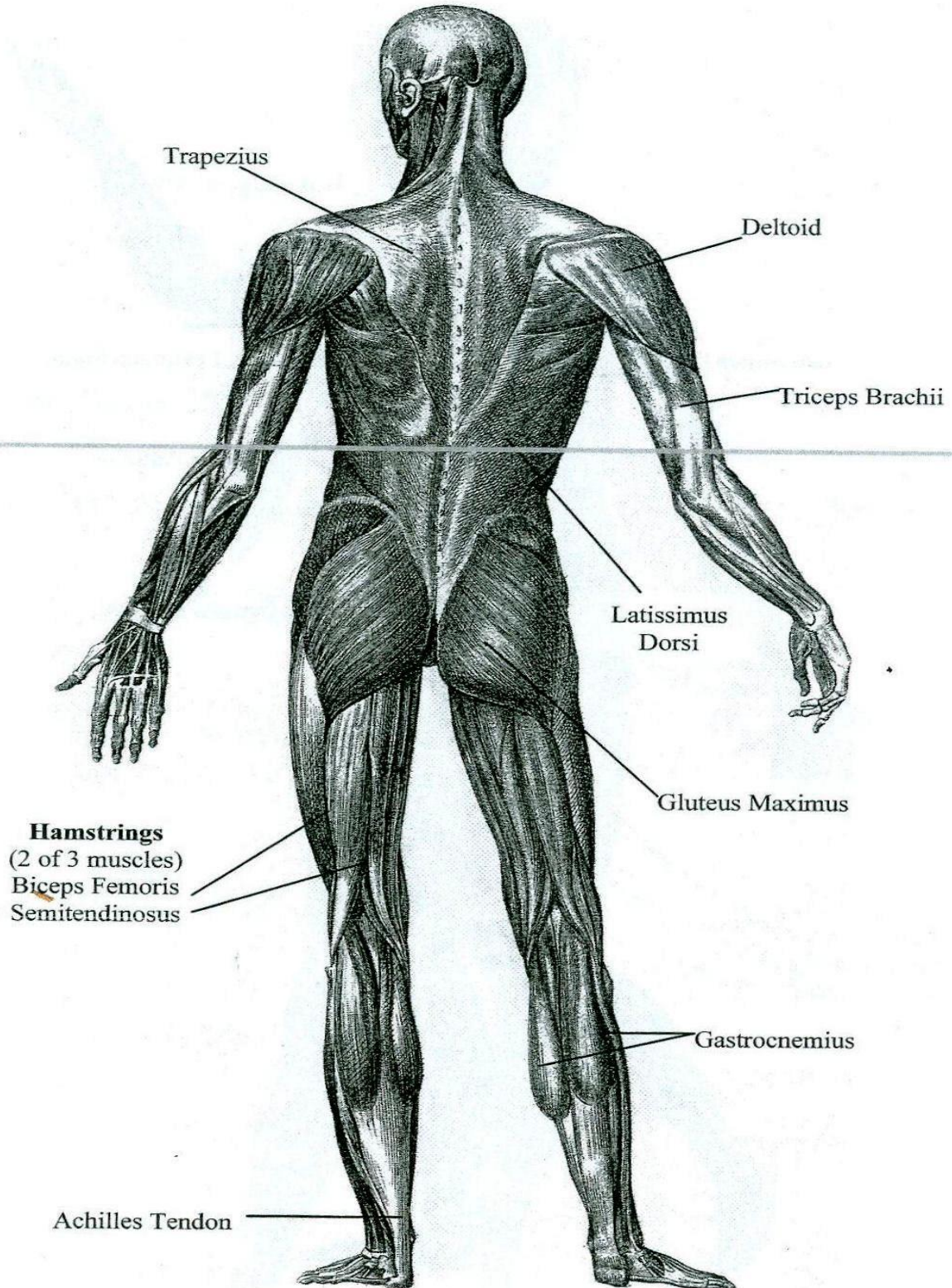
From Heck's Pictorial Archive of Nature and Science

Superficial Muscle Layer - Anterior View

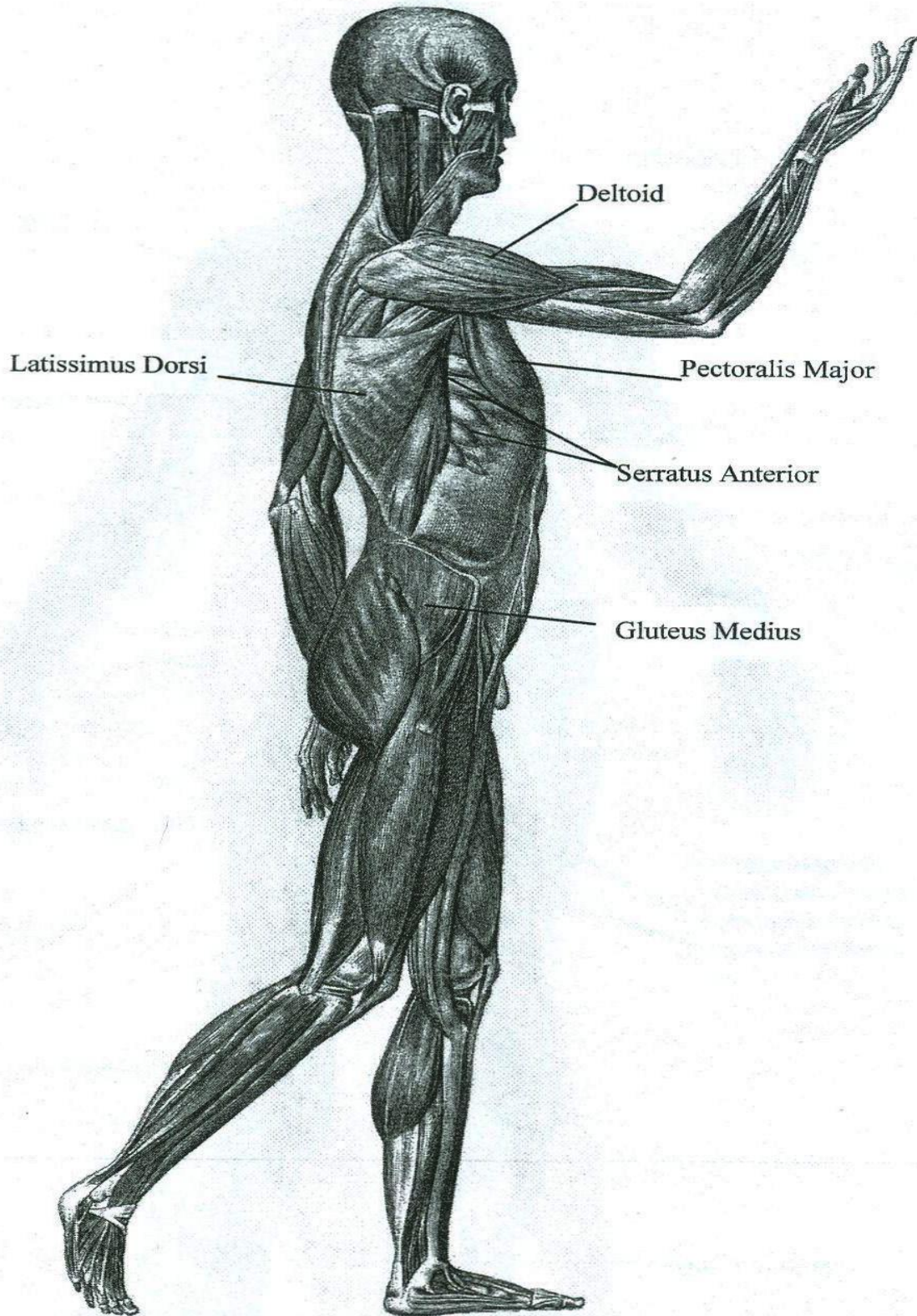


From Heck's Pictorial Archive of Nature and Science

Superficial Muscle Layer - Posterior View

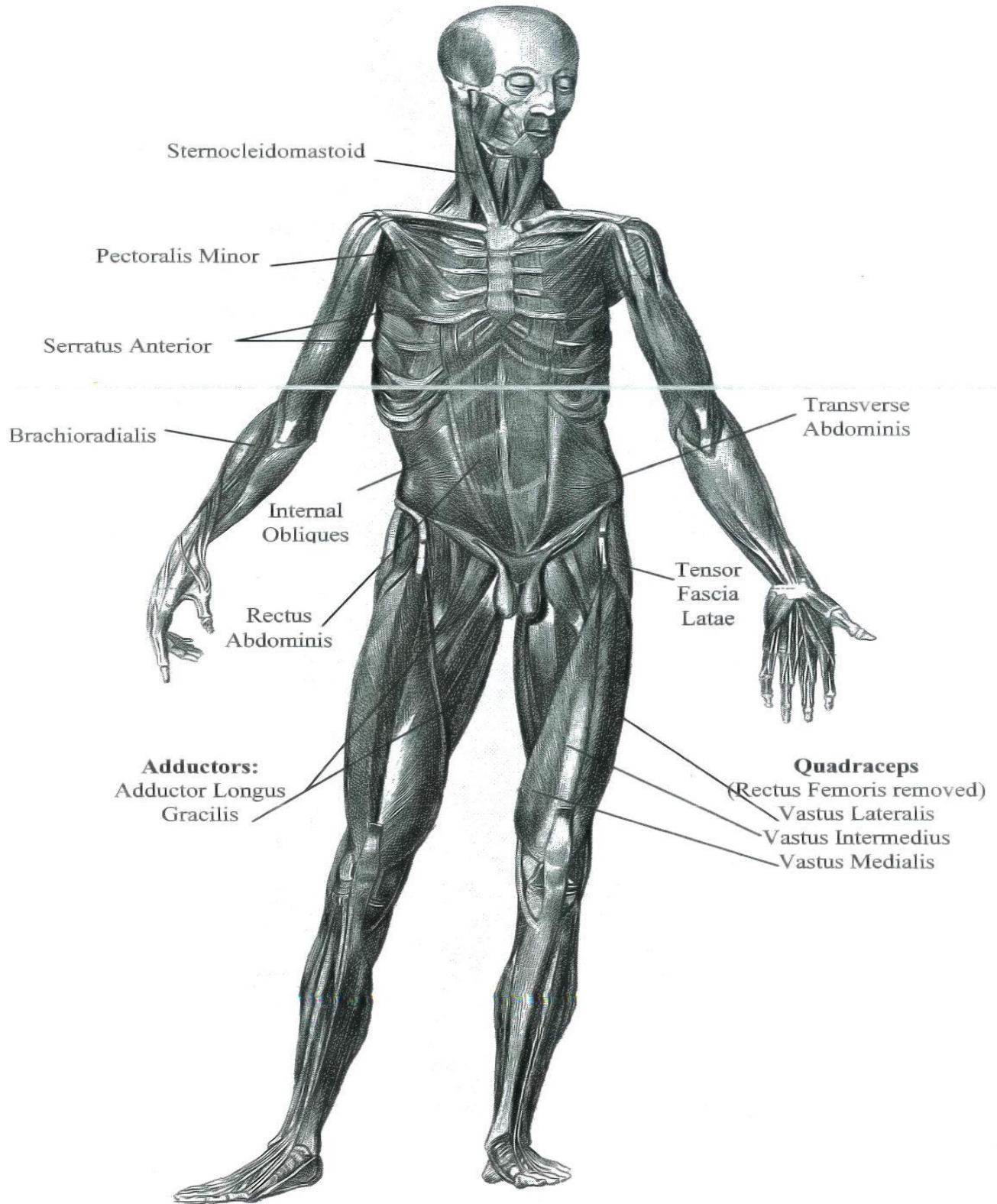


Superficial Muscle Layer - Lateral View

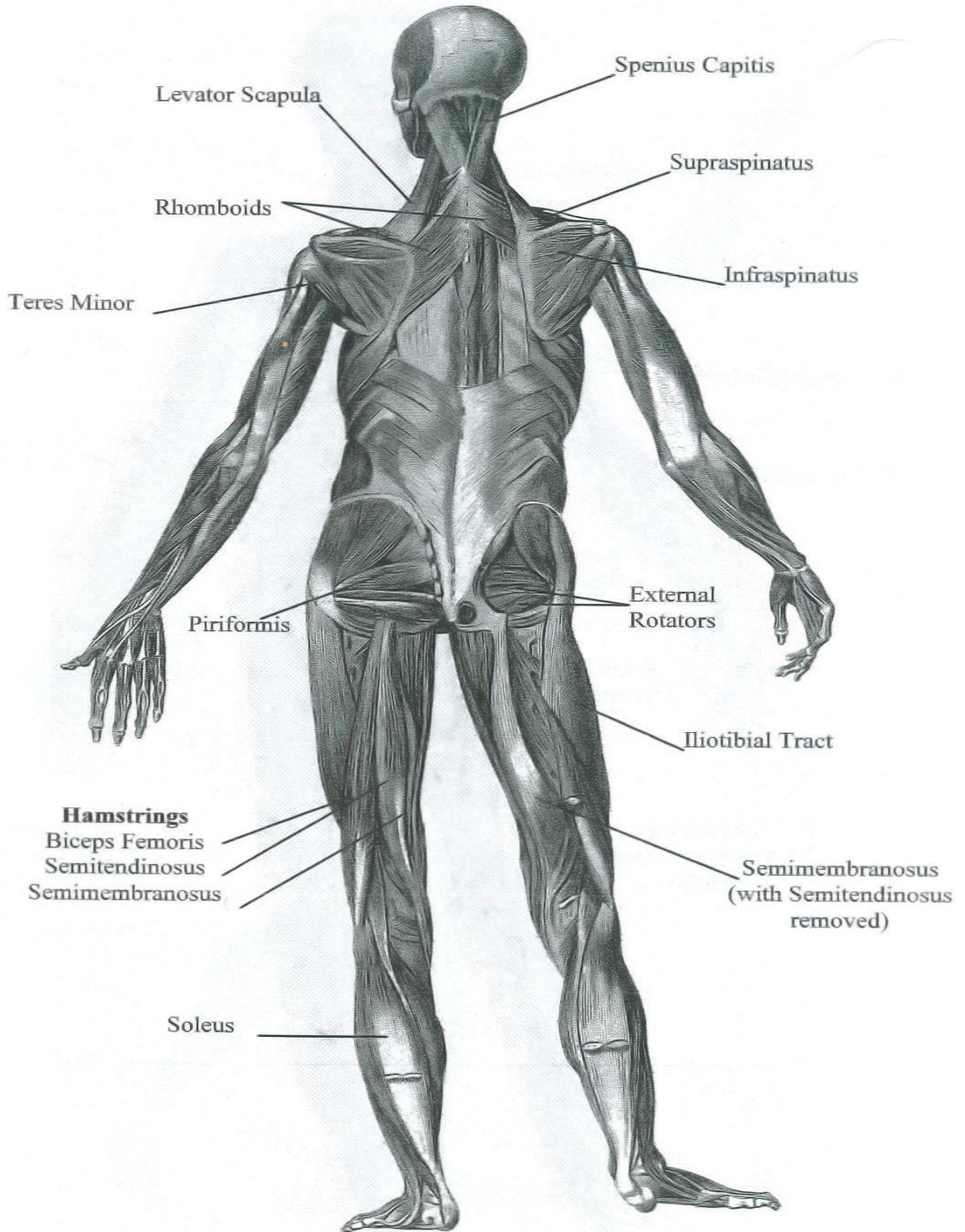


From Heck's Pictorial Archive of Nature and Science

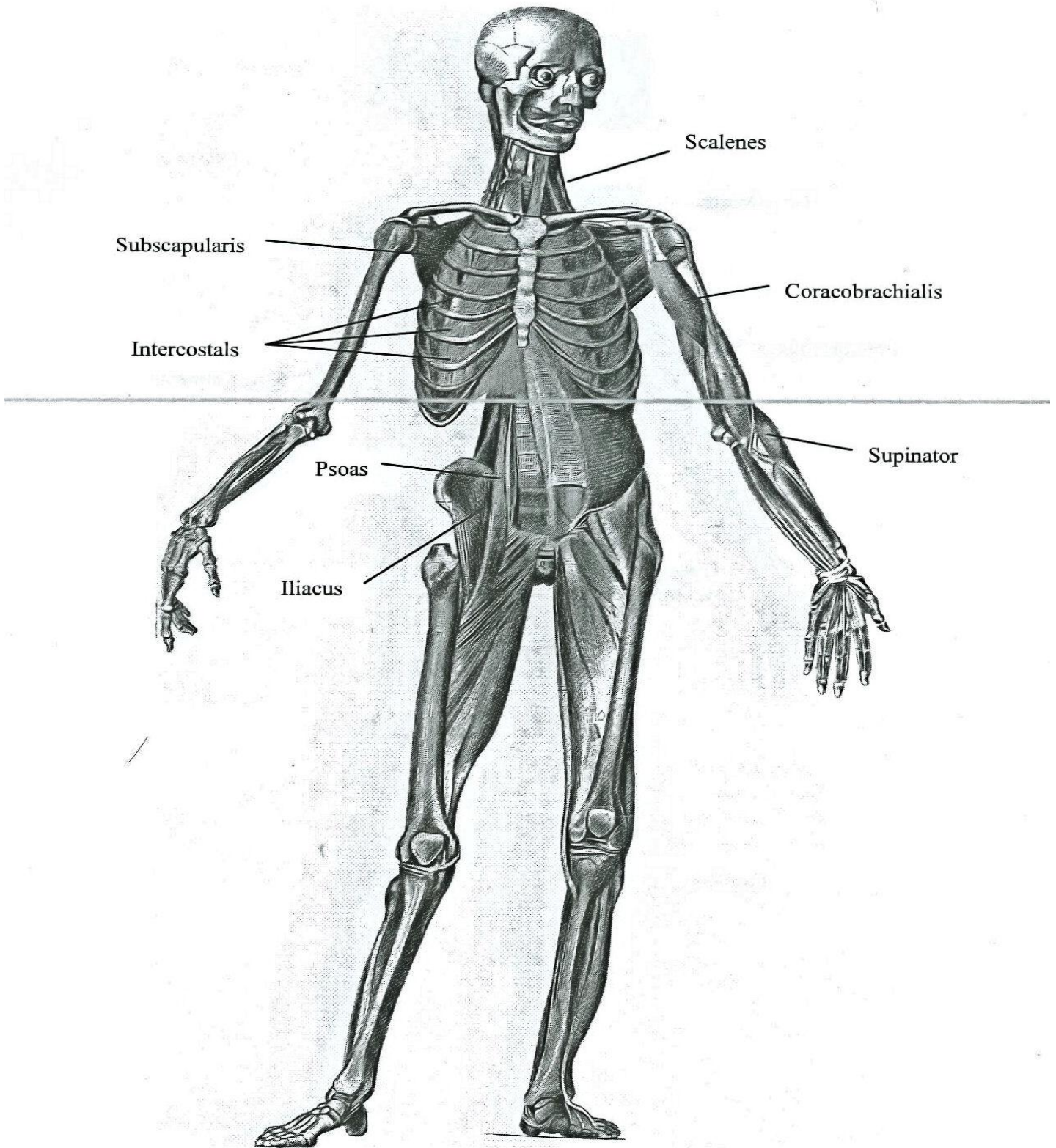
Intermediate Muscle Layer – Anterior View



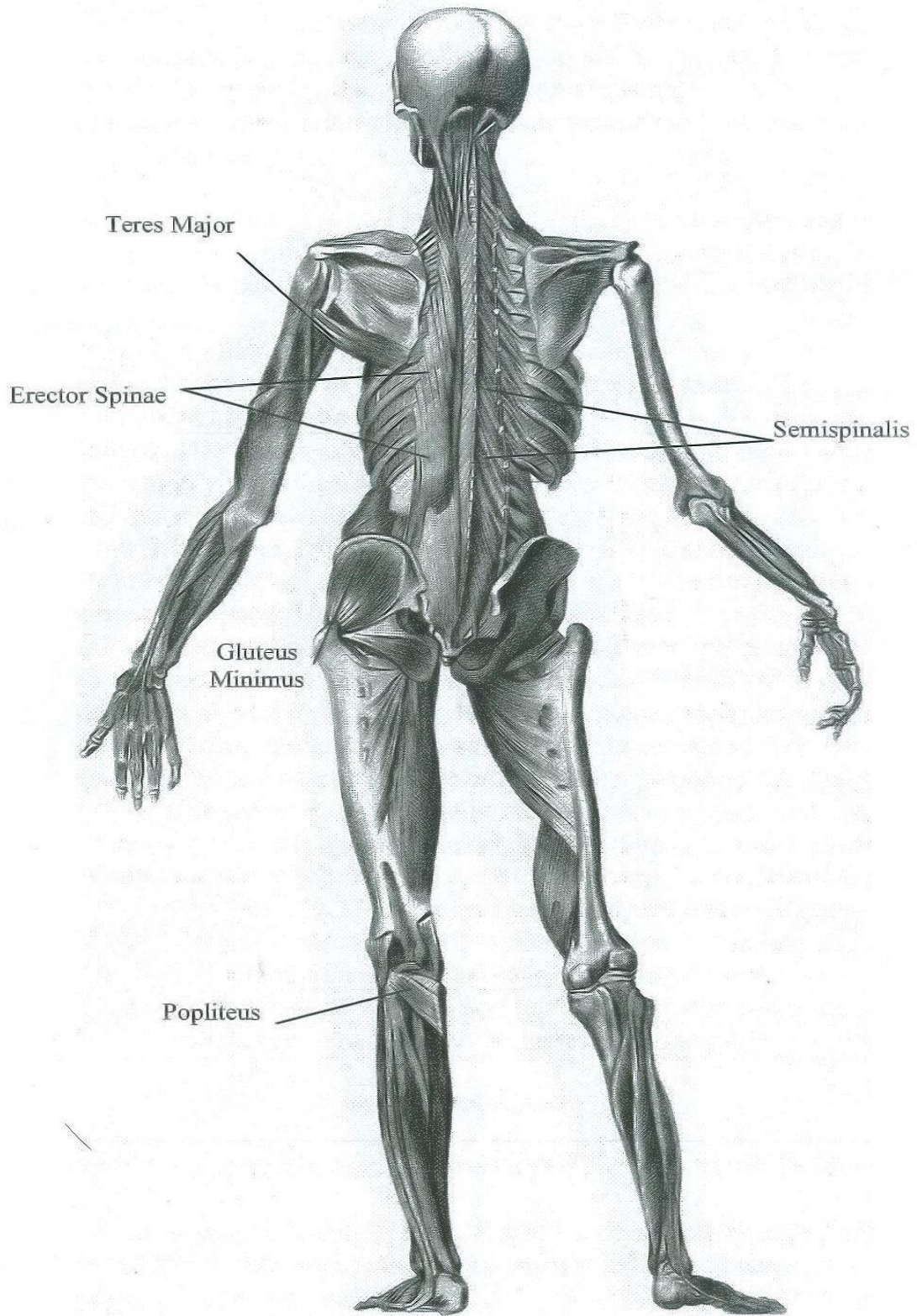
Intermediate Muscles Layer – Posterior View



Deep Muscle Layer – Anterior View



Deep Muscle Layer – Posterior View



From Heck's Pictorial Archive of Nature and Science